

УДК 616-006.3

SUCCESSFUL RESECTION OF A RETROPERITONEAL GIANT SARCOMA: A CASE REPORT

Voronov Iosif A.¹, Bugaycov Sergey G.², Mashukov Artem A., Raciborsky Dmitry V.¹, Bilenko Aleksandr A.²

¹Odessa Regional Oncological Center, Odessa, Ukraine

²Odessa State Medical University, Odessa, Ukraine

Key words: tumor, sarcoma

Successful surgical resection of a giant 38 kilogram retroperitoneal sarcoma was performed in a 52-year-old patient.

Soft-tissue sarcomas represent a heterogeneous group of rare tumors arising from the mesenchymal cells of the connective tissue. The diagnosis is frequently made later in the progress of the disease due to the absence of specific symptomatology. Surgery with total resection of the tumor is the treatment of choice, but is an option in only 38 to 75% of cases [1]. Successful operative resection can grant prolonged disease-free survival and cure for retroperitoneal sarcomas [2].

Approximately 15% of soft tissue sarcomas arise in the retroperitoneum. These neoplasms are locally aggressive and the only curative treatment is surgical resection "en-bloc". The main cause of mortality is locoregional recurrence. Five-year survival is 3-58%, depending on the histological subtype and grade and on the possibility of complete resection [3]. The most frequent clinical signs of retroperitoneal sarcomas are abdominal pain and the appearance of a mass upon self-examination or physical examination.

Case Report

A 52-year-old male with a palpable mass in the abdomen was admitted to Odessa Oncological Center's Department of Abdominal Surgery. The patient presented with constant pain in the mesogastric region, enlargement of the abdomen, palpable tumor, nausea, weakness, decreased appetite, and weight loss of 10 kg within the last month. These symptoms

lasted for three months and progressively worsened in the month before the patient was admitted to the hospital. Particularly, the patient experienced increasing abdominal pain and enlargement of the abdomen. CT scan of the abdomen was performed and a giant heterogeneous mass 285 x 207 mm was revealed in the abdomen and retroperitoneal space along with ascites. Also, retroperitoneal lymph nodes 5-8 mm in diameter were discovered on CT. A 17 mm hypodense area was also seen at the head of the pancreas.

The patient underwent a laparotomy. On exploration, 150 ml of ascitic fluid was found. A retroperitoneal tumor was revealed and described as movable, solid, lumpy, and dark blue in color, with necrotic areas. The tumor measured 46 x 35 x 25 cm and occupied the entire abdominal cavity. There were ingrowths of tumor into the posterior wall of the bladder, growing up to the intestine, colon, stomach, and front of the abdominal wall. The surface of the spleen and liver were not involved and there were no liver metastases. A retroperitoneal tumor was revealed as resectable. With technical difficulties, the tumor was separated from the organs. The tumor was separated from the colon, intestine, and front abdominal wall. We performed bladder resection of six centimeters of the posterior wall of the bladder. Resection of the posterior wall of the bladder was performed with further suturing.

On gross examination, the tumor was solid, heterogeneous, lumpy, dark blue colored, with necrotic regions, and weighing 38 kilograms with dimensions of 46 x 35 x

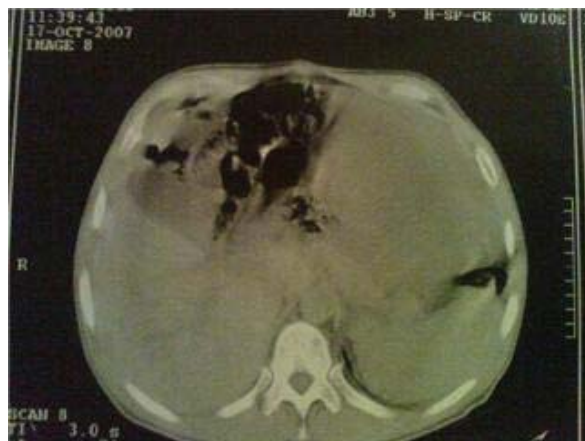

Figure 1. CT scan of abdomen: heterogeneous mass 285x207 mm.

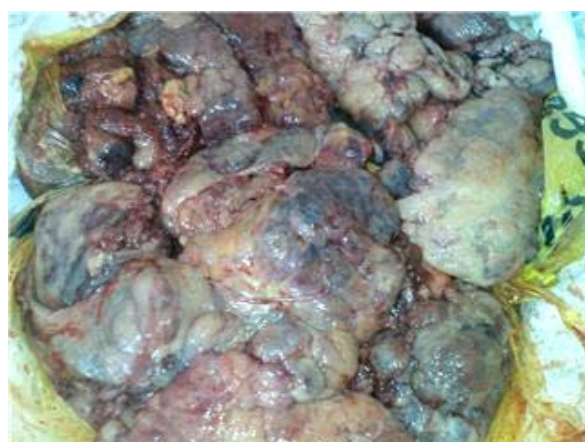

Figure 2. 38 kilogram retroperitoneal tumor.

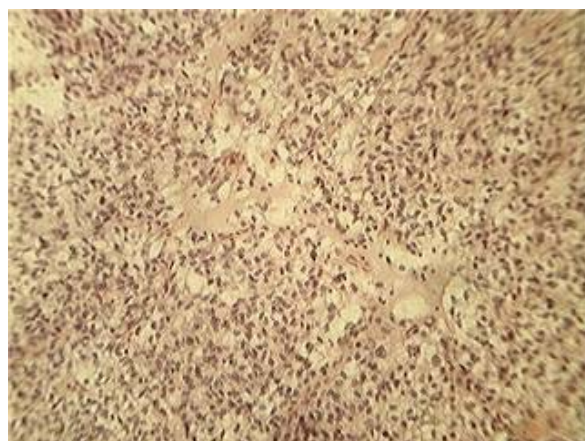


Figure 3. Low-differentiated epithelioid malignant sarcoma

25 cm (Figure 1). Histopathologic diagnosis was made as a low-differentiated epithelioid malignant sarcoma (Figure 2).

The patient was referred for adjuvant chemotherapy which was rejected. There

were no post operative complications and the patient has been doing very well for 4 months after surgery.

References

1. Joual A, Faik H, Rabii R, Hafiani M, Bennani S, el Mrini M, Benjelloun S. Retroperitoneal sarcoma: report of 6 cases. [Article in French]. *Ann Urol (Paris)*. 2000 Jun;34(3):175-8.
2. Perez EA, Gutierrez JC, Moffat FL Jr, Franceschi D, Livingstone AS, Spector SA, Levi JU, Sleeman D, Koniaris LG. Retroperitoneal and truncal sarcomas: prognosis depends upon type not location. *Ann Surg Oncol*. 2007 Mar; 14(3):1114-22. Epub 2007 Jan 7.
3. Марнн-Gymez LM, Vega-Ruiz V, Garcna-Ureca MA, Navarro-Picero A, Calvo-Durбн A, Dnaz-Godoy A, de la Vega Olnas MC. Retroperitoneal sarcomas. Report of five new cases and review of the current situation. [Article in Spanish]. *Cir Esp*. 2007 Sep;82(3):172-6.

Резюме

ОПИСАНИЕ СЛУЧАЯ УСПЕШНОЙ РЕЗЕКЦИИ ГИГАНТСКОЙ РЕТРОПЕРИТОНЕАЛЬНОЙ САРКОМЫ

Воронов И.А., Бугайков С.Г., Машуков А., Рациборский Д.В., Биленко А.А.

Описан клинический случай успешной хирургической резекции гигантской 38 килограммовой ретроперитонеальной саркомы у 52-летнего пациента.

Ключевые слова: опухоль, саркома

Резюме

ОПИС ВИПАДКУ УСПІШНОЇ РЕЗЕКЦІЇ ГИГАНТСЬКОЇ РЕТРОПЕРИТОНЕАЛЬНОЇ САРКОМИ

Воронів І.А., Бугайков С.Г., Машуков А., Рациборський Д.В., Біленко А.А.

Описаний клінічний випадок успішної хірургічної резекції гігантської 38 кілограмової ретроперитонеальної саркоми у 52-річного пацієнта.

Ключові слова: пухлина, саркома

Впервые поступила в редакцию 06.05.2010 г. Рекомендована к печати на заседании редакционной коллегии после рецензирования