

BREAST CANCER WITH DIABETES INSIPIDUS

M. Dogan¹, E. Karakilic², I.I. Oz³, F. Zorlu⁴, H. Akbulut¹, *

¹Ankara University School of Medicine, Departments of Medical Oncology

²Internal Medicine, ³Radiodiagnostic, Ankara 06590, Turkey

⁴Hacettepe University School of Medicine, Department of Radiation Oncology, Ankara 06100, Turkey

Diabetes insipidus (DI) is a rare clinical condition, which is usually caused by neurohypophyseal or pituitary stalk infiltration in cancer patients. **Case report:** we present a 62-year old metastatic breast cancer woman with DI. She admitted to the hospital because of nausea, vomiting, polyuria and polydipsia, while she was on no cytotoxic medication. She had no electrolyte imbalance except mild hypernatremia. The CT scan of the brain yielded a suspicious area in pituitary gland. A pituitary stalk metastasis was found on magnetic resonance imaging (MRI) of pituitary. Water deprivation test was compatible with DI. A clinical response to nasal vasopressin was achieved. **Conclusions:** Cancer patients who have symptoms such as nausea, vomiting, polyuria and polydipsia while they are not on chemotherapy should be evaluated for not only metabolic complications like hypercalcemia but also posterior pituitary or stalk metastasis MRI could be the choice of imaging for pituitary metastasis.

Key Words: cancer, diabetes insipidus, pituitary metastasis.

Arginine vasopressin (AVP, secreted from hypothalamus, is a multifunctional neurotransmitter that plays an important role in water homeostasis [1]. Diabetes insipidus (DI) is a metabolic disorder which is caused by disturbance in either AVP secretion or function. It is characterized with large quantities of urine output with low density (> 50 ml/kg, osmolarity < 300 mosmol/L) [2]. Granulomatous diseases (i. e. tuberculosis, histiocytosis and neurosarcoidosis), hematological malignancies (i. e. leukemia and lymphoma) and solid tumors such as breast cancer may cause primary central DI. Pituitary metastasis in cancer patients is rare, Most of the reported DI is caused in patients with either lung or breast cancers [3].

A 62-year old metastatic breast cancer woman was admitted to the hospital with serious nausea, vomiting, polyuria and polydipsia after 4 months of follow-up period without any medication. She had a local recurrence of invasive ductal carcinoma after a 17 year of remission period. The patient had been followed for an additional 9 years without any local or distant metastasis. Four years ago, she developed a lobular carcinoma in contra lateral breast, which was surgically removed. Three years later she had local and distant metastasis. Distant metastases were in skeletal system with multiple involvement, and in ovaries. Later liver and lung metastases have also recurred.

The patient's vomiting was unrelated with foods and not projectile. She had no drug history. On examination, her performance status was 2 (ECOG), and the rest of the physical examination was normal. Despite vomiting, the patient had no signs or symptoms of dehydration vomiting and, no remarkable finding on neurological and otorhinolaryngologic examination except presbycusis. Laboratory tests on admission were as follows: creatinine: 1.09 mg/dl (Normal:0.5–0.9 mg/dl), sodium:

144 mmol/L (normal: 136–146 mmmol/L), potassium: 3.45 mmol/L (3.5–5.1 mmol/L), calcium: 9.44 mg/dl (normal: 8.6–10.2 mg/dl), albumin: 3.5 g/dl (normal: 3.5–5.2 g/dl), lactate dehydrogenase (LDH): 617 U/L (normal: 240–480 U/L). Upper gastrointestinal endoscopic biopsy was compatible with activated chronic atrophic gastritis. The CT scan of the brain (BCT) yielded a suspicious area in pituitary gland (Fig. 1). On the third day of admission, serum sodium levels started rising daily (147–154 U/L). She had polyuria during hypernatremia, but no neurological findings. Serum osmolarity was in upper normal limit [293 mosmol/kg (normal: 275–295 mosmol/kg)]; urine osmolarity was 122 mosmol/kg (repeated values were 324.78 mosmol/kg and 203.3 mosmol/kg; normal range: 600–850 mosmol/kg)]; urine sodium was 31 mmol/L (repeated value was 6 mmol/L]; urine density was 1002 (repeated values were 1008 ve 1007). The water deprivation test was in consistent with DI. She had high basal serum osmolarity (306 mosmol/kg), low urine osmolarity (234 mosmol/kg) and density (1006) whereas high serum osmolarity (303 ve 310 mosmol/kg), and both low urine osmolarity (263 ve 321 mosmol/kg) and density (1009 ve 1011) at second-hour and later on water deprivation test. On MR imaging of the brain, a 13 x 10 mm lesion including cystic component on posterior part of stalk, which was considered as metastasis on was noticed (Fig. 2, a, b). Prolactin level was high [76.57 ng/ml; normal: 6–30 ng/ml] whereas both insulin like growth factor-1 (IGF-1) and was growth hormone (GH) levels were low [69.4 ng/ml for IGF-1; normal range: 94–269 ng/ml and 0.01 ng/mL for GH; normal range: 0.09–3.83]. She was given Arginin/Vasopressin (AVP) nasal spray, 20 mcg bid / day and applied 'cyber-knife' (total 1500 cGy) for stalk metastasis. The symptoms of polyuria, nausea and vomiting decreased on the third day of the treatment, and hypernatremia recovered on the fourth day. Fulvestrant (every 28 days, 250 mg/day, intramuscular) was given after her symptoms had improved. She had been applied fulvestrant for five months; however, she died because of disease progression at the sixth month of DI diagnosis.

Received: October 16, 2008.

*Correspondence: Fax: 00903123192283

E-mail: mutludogan1@yahoo.com

Abbreviations used: AVP – arginine vasopressin; BCT – CT scan of the brain; DI – diabetes insipidus; MRI – magnetic resonance imaging.

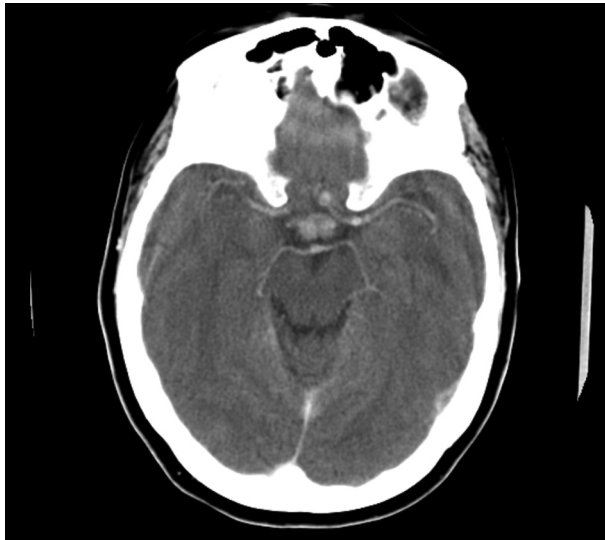


Fig. 1. A suspicious enhancement in pituitary gland was found on CT after intravenous contrast injection

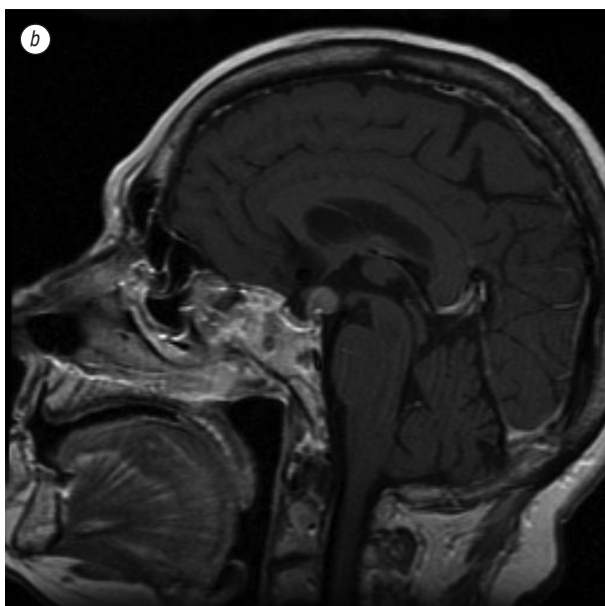
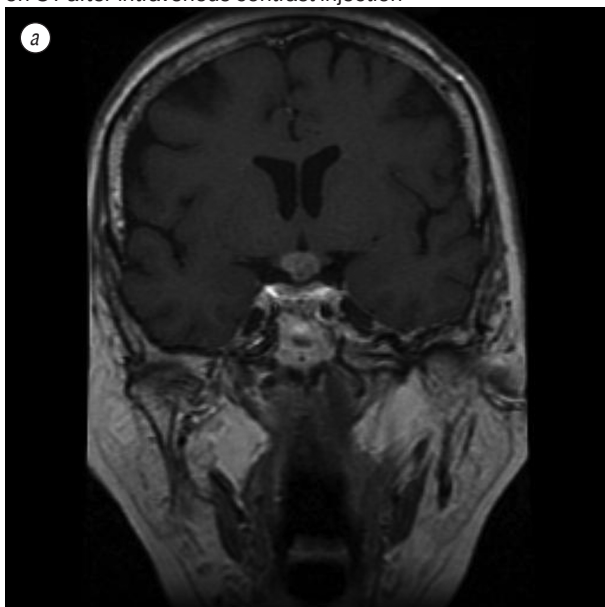


Fig. 2. A lesion including cystic component on posterior part of stalk was found on coronal (a) and midsagittal (b) MR sections of the cranium after intravenous contrast injection

Metastasis to the pituitary gland is an uncommon site of metastasis of cancer. Breast and lung cancer are the two most common tumours that spread to the pituitary gland. Diabetes insipidus is rare in cancer patients. Teears *et al.* [4], reported that 69,3% of 88 cancer patients with hypophyseal metastasis had posterior pituitary alone or both anterior and posterior pituitary metastasis, and 6,8% of them had DI. Pituitary MRI is the most useful imaging modality for pituitary pathologies [5]. Hypophysis, stalk, cavernous sinuses, sphenoid sinus and optic chiasma are well evaluated on coronal and sagittal T1-weighted MRI both before and after Gadolinium injection [6]. Lesions on MRI may be seen as cystic, nodular or stalk thickening. Poullin *et al.*, [7] concluded that a patient who had been diagnosed breast cancer 10 years ago had DI secondary to pituitary metastasis according to the symptoms, such as polydipsia and polyuria, with stalk thickening on pituitary MRI. Furthermore, the patient improved after AVP application [7]. Hypophyseal, especially stalk, pathologies may not be so clear on BCT. Our patient was suspected for pituitary metastasis on BCT, but it was more definitive on MRI. Radiotherapy is among the treatment modalities of pituitary metastasis. However, gamma-knife or cyber-knife is also available for the patients who had been treated with radiotherapy before. Piedra *et al.* [8] reported that treatment necessity of a cancer patient with DI related to stalk metastasis decreased after gamma-knife. We also applied cyberknife with 15 Gy. In spite of good response to treatment, the breast cancer patients with pituitary metastasis and DI have poor prognosis with a median survival time of 6 months [9, 10]. The diagnosis of DI should be kept in mind in breast cancer patients with symptoms of serious nausea, vomiting, polyuria and polydipsia.

REFERENCES

1. Majzoub JA, Srivatsa A. Diabetes insipidus: clinical and basic aspects. *Pediatr Endocrinol Rev* 2006; **4**: 60–5.
2. Robertson GL. Disorders of the neurohypophysis. In: Kaper DL, Braunwald E, Fauci AS, Hauser SL, Longo DL, Jameson JL, eds. 16th Ed. *Harrison's Principles of Internal Medicine*. The United States of America: the McGraw-Hill Companies, 2005: 2098.
3. Granata A, Figura M, Gulisano S, *et al.* Central diabetes insipidus as a first manifestation of lung adenocarcinoma. *Clin Ter* 2007; **158**: 519–22.
4. Teears RJ, Silverman EM. Clinicopathologic review of 88 cases of carcinoma metastatic to the pituitary gland. *Cancer* 1975; **36**: 216–20.
5. Chaudhuri R, Twelves C, Cox TC, Bingham JB. MRI in diabetes insipidus due to metastatic breast carcinoma. *Clin Radiol* 1992; **46**: 184–8.
6. Melmed S, Jameson JL. Disorders of the anterior pituitary and hypothalamus. In: Kaper DL, Braunwald E, Fauci AS, Hauser SL, Longo DL, Jameson JL, eds. 16th Ed. *Harrison's Principles of Internal Medicine*. The United States of America: the McGraw-Hill Companies, 2005: 2082.
7. Poullin P, Di Costanzo V, Le Pommelet C, Gabriel B. Diabetes insipidus disclosing metastasis of breast adenocarcinoma. *Rev Med Interne* 1995; **16**: 444–6.
8. Piedra MP, Brown PD, Carpenter PC, Link MJ. Resolution of diabetes insipidus following gamma knife surgery

for a solitary metastasis to the pituitary stalk. Case report. J Neurosurg 2004; **101**: 1053–6.

9. Morita A, Meyer FB, Laws ER. Symptomatic pituitary metastases. J Neurosurg 1998; **89**: 69–73.

10. Kurkjian C, Armor JF, Kamble R, et al. Symptomatic metastases to the pituitary infundibulum resulting from primary breast cancer. Int J Clin Oncol 2005; **10**: 191–4.

РАК МОЛОЧНОЙ ЖЕЛЕЗЫ ПРИ НЕСАХАРНОМ ДИАБЕТЕ

Несахарный диабет (DI) — редкое клиническое состояние, вызываемое инфильтрацией нейрогипофизарной ножки или ножки гипофиза у онкологических больных. *Описание случая:* в исследовании рассмотрен случай выявления DI у 62-летней женщины, у которой был выявлен рак молочной железы с наличием метастазов. Она поступила в больницу с симптомами тошноты, рвоты, полиурии и полидипсии, хотя не проходила курса химиотерапии. У больной не выявлено дисбаланса электролитов, кроме небольшой гипернатриемии. Компьютерная томография мозга показала подозрительную область в мозговом придатке. На магнитно-резонансном изображении выявлен метастаз в ножке гипофиза. Обезвоживание также соответствовало диагнозу DI. Получен клинический ответ на назальный вазопрессин. *Выводы:* онкологические больные с симптомами тошноты, рвоты, полиурии и полидипсии, не проходящие курса химиотерапии, должны быть обследованы не только на предмет метаболических осложнений, таких как гиперкальциемия, но и на возможное наличие метастазов в ножке и задней части гипофиза с помощью магнитно-резонансного изображения.

Ключевые слова: рак, несахарный диабет, метастаз в гипофизе.