

## METFORMIN PLUS PIAF COMBINATION CHEMOTHERAPY FOR HEPATOCELLULAR CARCINOMA

B. Petrushev<sup>1, \*</sup>, C. Tomuleasa<sup>2,3, \*</sup>, O. Soritau<sup>3</sup>, M. Aldea<sup>1</sup>, T. Pop<sup>1,4</sup>,  
S. Susman<sup>1</sup>, G. Kacso<sup>1,5</sup>, I. Berindan<sup>1,6</sup>, A. Irimie<sup>1,7</sup>, V. Cristea<sup>1,4</sup>

<sup>1</sup>Department of Medicine — Iuliu Hatieganu University of Medicine and Pharmacy, Cluj Napoca

<sup>2</sup>Department of Medicine, Division of Gastroenterology and Hepatology, The Johns Hopkins University School of Medicine, Baltimore, MD, United States of America

<sup>3</sup>Department of Immunology, Ion Chiricuta Comprehensive Cancer Center, Cluj Napoca, Romania

<sup>4</sup>Octavian Fodor Regional Institute of Gastroenterology and Hepatology, Cluj Napoca, Romania

<sup>5</sup>Department of Medical Oncology, Ion Chiricuta Comprehensive Cancer Center, Cluj Napoca, Romania

<sup>6</sup>Department of Genetics, Ion Chiricuta Comprehensive Cancer Center, Cluj Napoca, Romania

<sup>7</sup>Department of Surgery, Ion Chiricuta Comprehensive Cancer Center, Cluj Napoca, Romania

**Objectives:** Metformin, the most used oral antidiabetic drug for the treatment of type 2 diabetes mellitus, has proved encouraging results when used in the treatment of various types of cancer such as triple-negative breast cancer. Despite compelling evidence of a role of metformin as an anticancer drug, the mechanisms by which metformin exerts its oncostatic actions are not fully understood yet. Therefore, we tried to bring new insights by analyzing the anti-neoplastic effect of metformin for hepatocellular carcinoma-derived stem-like cells treated with conventional combination chemotherapy. **Methods:** Cancer stem-like cells previously isolated from a hepatocellular carcinoma biopsy were treated with metformin, PIAF chemotherapy regimen and the combination of these two protocols. Measurements of lipid peroxidation, reduced glutathione, fluorescein diacetate and proliferation rates were determined, apart from the autophagy assay and apoptosis determination by chip flow cytometry. **Results:** Metformin alone and especially metformin in association with PIAF increases oxidative stress within the cells by increasing the levels of lipid peroxids as well as decreasing the levels of reduced glutathione. The MTT cell proliferation assay showed decreased proliferation rates for the arm treated with metformin and with the combination of drugs in comparison with the control arm, proving high correlation with the oxidative stress results. The autophagy assay and determination of apoptosis by chip flow cytometry confirmed the results obtained in the previous assays. **Conclusion:** Metformin could be used in chemotherapy treatments to induce reactive oxygen species and increase the cytostatics effects within the tumor cell. Still, further experiments must be carried out on murine models before we can move on and use this drugs in the adjuvant setting for unresectable primary liver cancer.

**Key Words:** metformin, chemotherapy, hepatocellular carcinoma, stem-like cells.

In ancient times, hepatology was inexistent, and liver was a source of legends and spirituality. Two thousand years BC the liver was thought to bear the soul and priests used hepatoscopy in animals as a tool for divine connection in order to predict the future and the outcome of a certain military endeavor [1, 2]. One of the most famous legends was written by Hesiod and describes Prometheus stealing fire from Zeus, before being punished by the king of the gods to be chained to a rock and having his liver eaten by an eagle. But the liver regenerated and regained its normal size overnight [3, 4]. Over time, the progress in the field of hepatology and liver surgery was mostly for oncologic diseases, becoming more and more accurate and sophisticated and years passed. An important step for the improved outcome is the understanding that liver cancer must be treated in specialized, interdisciplinary centers where a close relationship between surgery, internal medicine and basic research have the common goal to diagnose and cure this infermity.

Liver cancer is the 6<sup>th</sup> most common cancer worldwide and the third most common cause of cancer mortality on the planet, with more than half a million deaths annually, indicating that this pathology is not only common, but also deadly. The highest incidence rates are in sub-Saharan Africa and eastern Asia, with China accounting for more than 50% of cases [5]. Hepatocellular carcinoma (HCC) incidence is high among young adults and varies among different populations and races, suggesting that this neoplasia is caused by several etiological factors, the synergy of whom has been shown to be significant in hepatocarcinogenesis. Risk factors include hepatitis B virus and hepatitis C virus infection, alcohol consumption, smoking, aflatoxin E exposure, hormonal intake, occupational exposures and chronic medical conditions such as metabolic syndrome, diabetes mellitus, obesity or even thyroid diseases [6]. Most cases of hepatocellular carcinoma are diagnosed in an advanced stage because of the relatively scarce symptoms. The patients survival depends not only on tumor characteristics, but also on the extent of the underlying disease. Furthermore, the therapeutic agents available for HCC and the indications for aggressive therapy expand and an increase of an interdisciplinary approach between surgery, ra-

Received: December 8, 2011.

\*Correspondence: E-mail: ciprian.tomuleasa@gmail.com

Authors marked with (•) contributed equally to this paper.

**Abbreviations used:** CSC – cancer stem-like cells; HCC – hepatocellular carcinoma; PIAF – Cisplatin/Interferon  $\alpha$ -2b/ Doxorubicin/5-Fluorouracil, with Capecitabine replacing 5-Fluorouracil.

diotherapy and chemotherapy is expected to challenge our understanding of prognostic factors for HCC [7].

Encouraging results have recently emerged from data published on breast cancer and point towards metformin, an oral-antidiabetic used for decades in the treatment of type 2 diabetes mellitus, as an efficient anticancer drug [8]. Metformin has already been investigated by our team for the treatment of WHO grade III and IV malignant gliomas in the laboratory settings [9], results being confirmed by retrospective epidemiological studies that reported a decrease in cancer risk and also a better response to chemotherapy of diabetic patients with breast cancer treated with metformin [10].

In the current research paper, we studied the effect of metformin plus PIAF (Cisplatin/Interferon  $\alpha$ -2b/Doxorubicin/5-Fluorouracil, with Capecitabine replacing 5-Fluorouracil) with combination chemotherapy on malignant liver stem-like cells in order to further investigate the basic mechanisms by which this association of drugs exerts its action on the cancer cell. The aim of the current paper is to investigate the correlation between an old drug and the best standard-of-care for unresectable hepatocellular carcinoma, with the final goal of improving the therapeutic index of such patients.

## MATERIALS AND METHODS

**Reactives.** Metformin (1,1-dimethylbiguanide hydrochloride) was purchased from Wurweg Pharma (Bucharest, Romania) and used in a final concentration of 10 mM diluted in phosphate buffer solution (PBS). It was added prior to a slightly modified PIAF regimen, with capecitabine replacing 5-fluorouracil, as according to the results of von Delius et al [11]. Doxorubicin was used at 0.5  $\mu$ g/mL, cisplatin at 0.25  $\mu$ g/mL, capecitabine at 30  $\mu$ g/mL and interferon  $\alpha$ -2b at 2  $\mu$ g/mL, corresponding to the concentrations used in the preclinical models that were later on followed by clinical trials [12]. N-Acetyl-L-Cysteine (NAC) was obtained from Organika (Bucharest, Romania) and used a final concentration of 25  $\mu$ g/ml, in order to fully assess the role of increased oxidative stress in the arm with metformin plus PIAF combination chemotherapy.

**Cell culture.** Cancer stem-like cells isolated as previously described [13] (CSC cell line), were cultured along with normal liver stem cells (LIV cell line) and the non-stem tumor cell line HepG2 (both kindly provided by the Assistant Professor Sergiu Susman, MD, PhD at Department of Histology, Iuliu Hatieganu University of Medicine and Pharmacy from Cluj Napoca, Romania) and maintained in Ham's F-12 and Dulbecco's Modified Essential Medium at 1:1 ratio, supplemented with 10% fetal calf serum (FCS), 100 U/mL penicillin and 100  $\mu$ g/mL streptomycin (all from Sigma Aldrich, St Louis, MO, USA) in a 37°C humidified incubator with a mixture of 95% air and 5% carbon dioxide. All experiments were performed on exponentially growing cells, with a doubling time of

approximately 24 to 36 h. These cells were previously reported to express the stem cell specific markers albumin,  $\alpha$ 1-antitrypsin,  $\alpha$ -fetoprotein, cytokeratin-18, telomerase, CD90 and CD133 [13, 14].

**Proliferation assay.** Cell survival was assessed using the MTT assay. For 3-(4,5-dimethylthiazol-2-yl)-2,5-diphenyltetrazolium bromide (MTT) assays, cancer cells in monolayer culture were cultivated at subconfluence in DMEM:F-12 media supplemented with 15% FCS, 100 U/mL penicillin and 100  $\mu$ g/mL streptomycin complete media before being washed twice with phosphate buffer solution (PBS). Cells were then incubated with trypsin-EDTA, resuspended in culture medium with FCS, counted and plated in 100  $\mu$ L media at  $15 \times 10^3$  cells/well in 96-well microtiter plates. After 24 h, cells were washed and treated with either metformin or N-Acetyl-L-Cysteine, before drugs being added. The control arms were compared with the corresponding conventional cytostatics at identical concentrations. Absorbance of the MTT was measured at 492 nm using a BioTek Synergy 2 fluorescence microplate reader (Winooski, VT, USA).

**Lipid peroxidation assay.** For both the determination of lipid peroxidation and reduced glutathion, cells were seeded in 75 ml flasks at a density of 3 millions cells/flask. At 24 and 48 h after treatments, cells were detached with trypsin and centrifugated 5 min, 2500 rpm, at 9°C. The supernatant was removed and the pellet was suspended in 1 ml lysis solution. Then each probe was sonicated to break the cellular membranes. Peroxidase activity was determined by using the indirect method that measures the rate of disappearance of NADPH, adapted to laboratory conditions. The reaction mixture consists of 1 mM GSH, 0.24 U/ml glutathione reductase and 0.15 mM NADPH in 50 mM pBS at a pH of 7. Appropriate volumes of samples were added for a final reaction mixture incubated at 37°C for 5 min. The assay was initially performed with 12 mM t-butyl hydroperoxide solution, before a decrease in absorbance at 340 nm for another 3 min. Lipid peroxidation activity was expressed as nmols NAPDH consumed/min/mg lipids and were calculated using  $6.2 \times 10^{-6}$  molar absorptivity for NAPDH, as according to Korde *et al.* [15].

**Reduced glutathione assay.** Reduced GSH is an intracellular antioxidant and is known to maintain cellular redox balance. We therefore measured intracellular GSH levels. Cell lysates were prepared as described above and analyzed for GSH levels through a fluorimetric method due to its property to make a fluorescent reaction with o-phthalaldehyde. Cells are mixed with acid trichloroacetic (TCA) 10% and after 10 min centrifuged. The supernatant was separated and 1.7 ml phosphate buffer with pH 8 and 1 ml of o-parafolmaldehyde were added. After 15 min the intensity of emission at 420 nm on an excitation of 350 nm was measured.

Glutathione concentration was measured using a calibration curve realized with known concentrations of glutathione obtained in the same way. Concentration values are expressed in nmol/ml.

**DiCloro-Fluorescein diacetate viability assay.**

96 wells plates were prepared in the same way as described in proliferation MTT assay, seeded with cells and incubated for seven days. For the viability test with fluorescein diacetate (FDA—an indicator of cell viability), cell monolayers were washed twice with PBS supplemented with  $Mg^{2+}$  and  $Ca^{2+}$  and stained for 5 min with FDA in the dark, at  $37^{\circ}C$  at a final concentration of 2,4 M. The wells were washed twice with PBS supplemented with  $Mg^{2+}$  and  $Ca^{2+}$  and fluorescence intensity (FI) and were measured at 488 nm using a BioTek Synergy 2 fluorescence microplate reader. All the experiments were performed in triplicate.

**Apoptosis quantification by chip flow cytometry.**

The cells were treated as described above and cultured for another 24 h. After incubation, the cells were trypsinized, collected, and stained with Anexinn V-Cy5 Apoptosis Detection Kit (BioVision) for 10 min in the dark. Calcein AM was used as a viability marker, the cells were incubated with 1  $\mu M$  Calcein AM for 30 min at  $37^{\circ}C$ , washed and quantified by on-chip flow cytometry according to the manufacturer instructions (Agilent Technologies). The number of apoptotic cells was assessed with Agilent Lab-on-a-chip Bioanalyzer 2100 (Agilent Technologies), as percent of apoptotic cells in live cells.

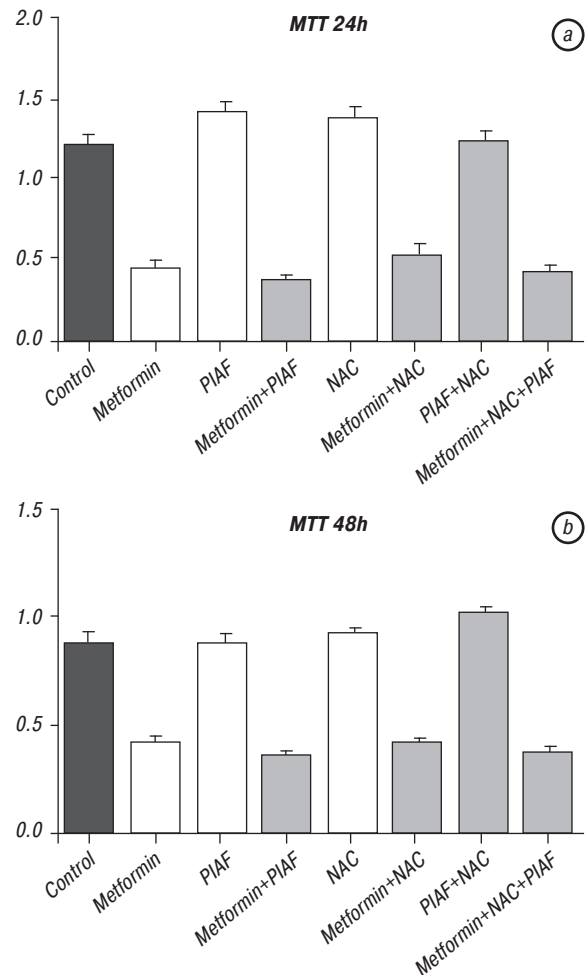
**Autophagy assay.** The autophagy assay was carried out using fluorescence microscopy and high-content imaging and analysis using cells previously fixed in 3.7% paraformaldehyde in PBS and permeabilized with 0.2% Triton X-100 diluted in PBS. Then, the cells were treated with 30–100  $\mu M$  chloroquine for 16 h, before the LC3B rabbit polyclonal antibody was diluted in blocking buffer in order to prepare 0.5  $\mu g/ml$  working solution. 3.7% formaldehyde in PBS was added and incubated for 15 min at room temperature before the fixative was removed and cells washed three times. The next step was to add 0.2% Triton X-100 in PBS and cells were incubated for 15 min at room temperature. The permeabilization buffer was removed, the primary antibody added to the cells and incubated for 1 h before being once again removed and cells washed three times. Cells were then incubated with an anti-rabbit secondary antibody for 45 min, washed three times once more and additional DNA counterstaining was carried out. Images were taken using a Zeiss Axiovert fluorescence microscope and autophagosomes looked like vesicular structures located in the perinuclear region.

**Data analysis.** Statistical significance values were obtained by a one-way analysis of variance (ANOVA) with 95% confidence level using GraphPad Prism 5 statistics program (La Jolla, CA, USA). Data were analyzed using one-way ANOVA with the Bonferroni multiple comparison test (Kruskal-Wallis as nonparametric). Statistical significance was set at  $p < 0.05$  and all experiments were performed in triplicate.

**RESULTS**

**Cell proliferation assay.** Metformin doesn't seem to inhibit hepatocellular carcinoma-derived cancer stem-like cell proliferation both at 24 h and after 48 h (Fig. 1,

a and 1, b). Nevertheless, the results are better when metformin plus PIAF combination chemotherapy was used and statistically significant data were obtained, as seen in Table 1 (at 24 h) and Table 2 (at 48 h). This is especially important because hepatocarcinoma stem-like cells have proven to be resistant to conventional treatment with cisplatin/doxorubicin/capecitabine.



**Fig. 1.** The MTT cell proliferation assay shows that the combination of metformin plus PIAF is the best combination chemotherapy option possible for hepatocellular carcinoma, both at 24 h (1 a) and 48 h (1 b). Data is statistically significant (95% confidence interval), as seen in Table 1 (data at 24 h) and Table 2 (data at 48 h)

**Table 1.** MTT assay at 24 h

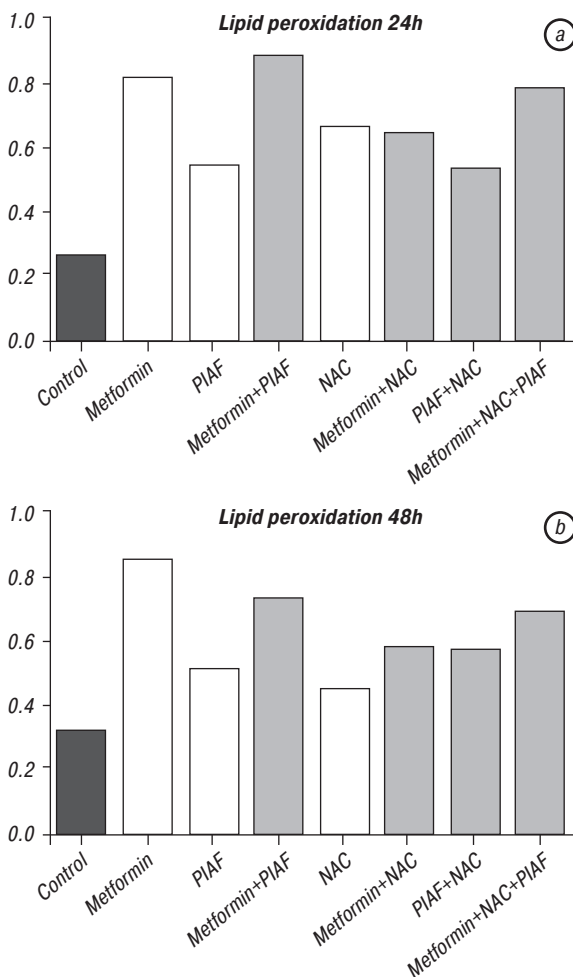
Statistically significant groups	95% CI of difference
Control vs Metformin	0.4726 to 1.058
Control vs Metformin + PIAF	0.5284 to 1.114
Control vs NAC + Metformin + PIAF	0.3860 to 0.9714
Control vs NAC + Metformin + PIAF	0.4878 to 1.073
Metformin vs PIAF	-1.293 to -0.6168
Metformin vs NAC	-1.267 to -0.5906
Metformin vs NAC + PIAF	-1.124 to -0.4476
PIAF vs Metformin + PIAF	0.6726 to 1.349
PIAF vs NAC + Metformin + PIAF	0.5302 to 1.206
PIAF vs NAC + Metformin + PIAF	0.6320 to 1.308
Metformin + PIAF vs NAC	-1.322 to -0.6464
Metformin + PIAF vs NAC + PIAF	-1.179 to -0.5034
NAC vs NAC + Metformin + PIAF	0.5040 to 1.180
NAC vs NAC + Metformin + PIAF	0.6058 to 1.282
NAC + Metformin + PIAF vs NAC + PIAF	-1.037 to -0.3610
NAC + PIAF vs NAC + Metformin + PIAF	0.4628 to 1.139

**Determination of lipid peroxidation.** Metformin increases the values of lipid peroxidation, both when used alone or when combined with conventional che-

motherapy drugs at 24 and 48 h, as seen in Fig. 2, *a* and 2, *b*. The most increased values of oxidative stress correspond to the lowest proliferation rates obtained with the treatment metformin plus PIAF chemotherapy.

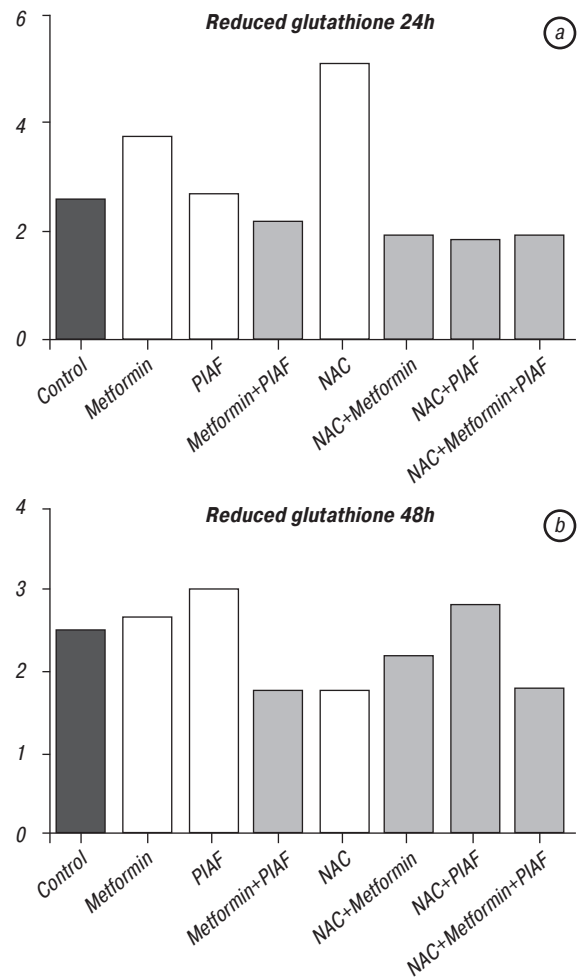
**Table 2.** MTT assay at 48 h

Statistically significant groups	95% CI of difference
Control vs Metformin	0.3236 to 0.5920
Control vs Metformin + PIAF	0.3742 to 0.6426
Control vs NAC + Metformin + PIAF	0.3206 to 0.5890
Control vs NAC + PIAF	-0.2736 to -0.005188
Control vs NAC + Metformin + PIAF	0.3686 to 0.6370
Metformin vs PIAF	-0.6104 to -0.3060
Metformin vs NAC	-0.6648 to -0.3604
Metformin vs NAC + PIAF	-0.7494 to -0.4450
PIAF vs Metformin + PIAF	0.3566 to 0.6610
PIAF vs NAC + Metformin + PIAF	0.3030 to 0.6074
PIAF vs NAC + Metformin + PIAF	0.3510 to 0.6554
Metformin + PIAF vs NAC	-0.7154 to -0.4110
Metformin + PIAF vs NAC + PIAF	-0.8000 to -0.4956
NAC vs NAC + Metformin + PIAF	0.3574 to 0.6618
NAC vs NAC + Metformin + PIAF	0.4054 to 0.7098
NAC + Metformin + PIAF vs NAC + PIAF	-0.7464 to -0.4420
NAC + PIAF vs NAC + Metformin + PIAF	0.4900 to 0.7944



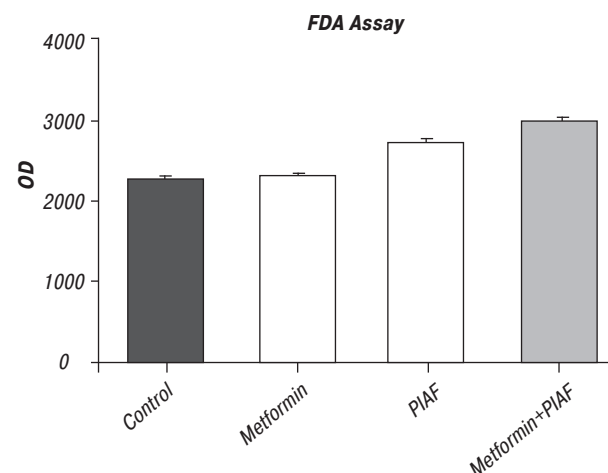
**Fig. 2.** Lipid peroxidation values at 24 h (*a*) and 48 h (*b*)

**Determination of reduced glutathione.** The initial hypothesis that oxidative stress plays a key role in the action of cytostatic drugs plus metformin in liver cancer cell inhibition is confirmed both by the data obtained from the determination of lipid peroxidation and reduced glutathione. Such, oxidative stress is most increased when using this combination chemotherapy, that is also corresponding to the lowest proliferation rates at 24 h (Fig. 3, *a*) and 48 h (Fig. 3, *b*).



**Fig. 3.** Determination of reduced glutathione at 24 h (*a*) and 48 h (*b*).

**Dicloro-FDA assay.** The FDA assay confirms our previous results, confirming increased oxidative stress in cells that were treated with metformin plus cytostatics, in comparison with cells treated either with metformin or PIAF, as illustrated in Fig. 4. Data are shown in Table 3.



**Fig. 4.** Determination of increased oxidative stress using the FDA assay

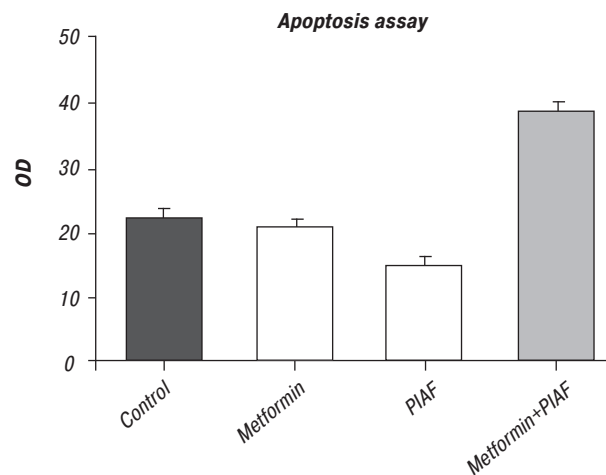
**Apoptosis assay.** After the incubation and staining with Anexinn V-Cy5 Apoptosis Detection Kit and using calcein AM as a viability marker, the Agilent Lab-on-a-chip Bioanalyzer 2100 technology allowed us to assess the percentage of cells in apoptosis



as further seen in Fig. 5. All the determinations were carried out in triplicate, according to data provided in Table 4.

**Table 3.** FDA assay

Statistically significant groups	95% CI of difference
Control vs PIAF	-632.2 to -267.8
Control vs Metformin + PIAF	-871.2 to -506.8
Metformin vs PIAF	-545.6 to -181.2
Metformin vs Metformin + PIAF	-784.6 to -420.2
PIAF vs Metformin + PIAF	-421.2 to -56.77



**Fig. 5.** Apoptosis assay compares in triplicate all the 4 arms of our experiment, proving an increased apoptosis via oxidative stress in cells treated with metformin plus temozolomide. The data presented by using Agilent Lab-on-a-chip Bioanalyzer 2100 is seen in the image presented below

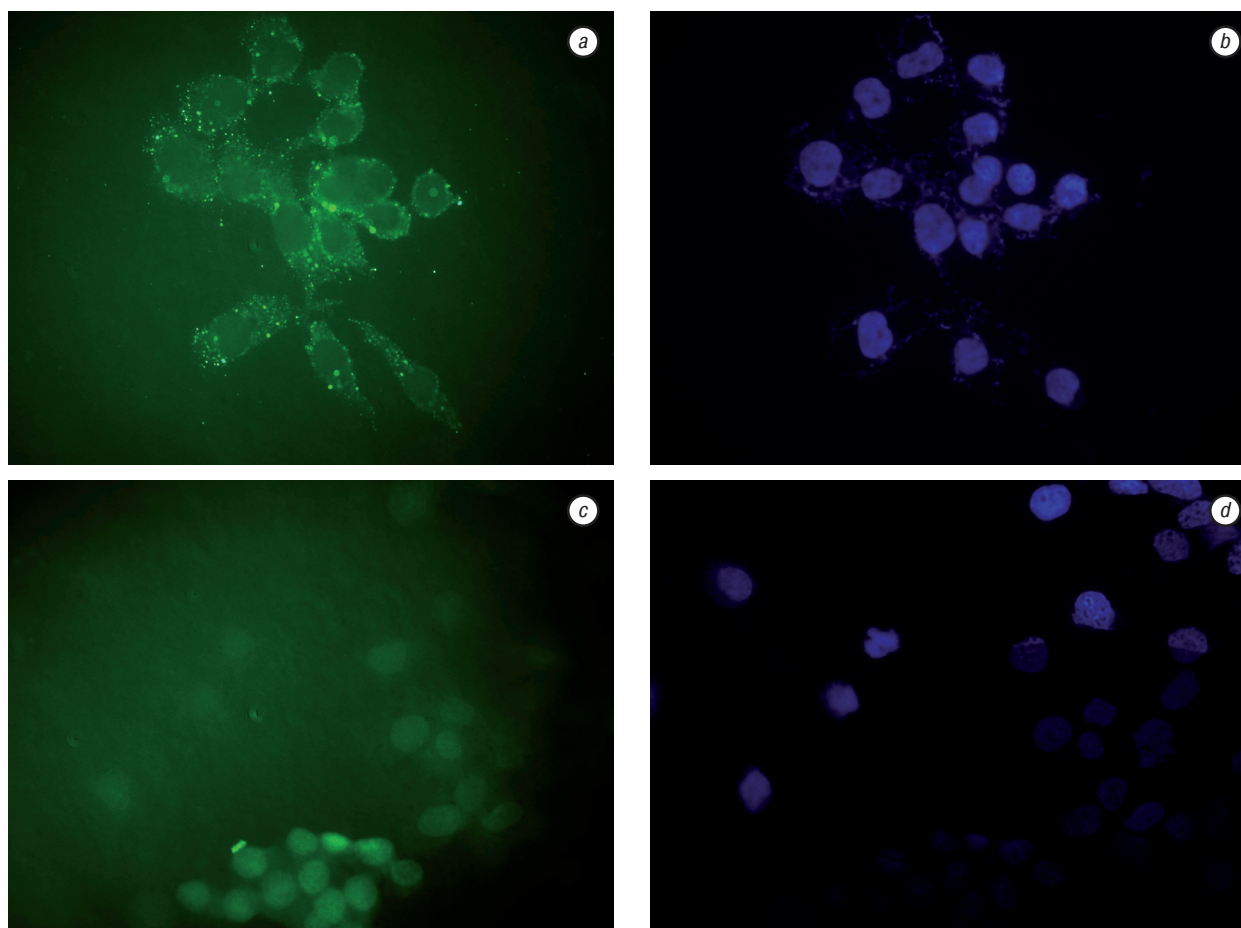
**Table 4.** Apoptosis assay

Statistically significant groups	95% CI of difference
Control vs Metformin + PIAF	-41.52 to -33.35
Metformin vs Metformin + PIAF	-41.62 to -33.45
PIAF vs Metformin + PIAF	-40.02 to -31.85

**Autophagy assay.** Autophagy is confirmed by Fig. 6 (a, b), in comparison with the control — as seen in Fig. 6 (c, d). In the case of metformin plus PIAF combination chemotherapy, vesicular-like structures are seen in the perinuclear region of the cells after incubation with the secondary anti-rabbit monoclonal antibody and counterstaining of the cell nucleus with DAPI (diamindino-2-phenylindole dye). Thus, our initial hypothesis and previous data obtained are confirmed.

**DISCUSSION**

Most cases of HCC are diagnosed in an advanced stage because of the relatively scarce symptoms. Thus, the oncologist must rely liver imaging in order to proper assess the exact number and size of liver lesions, the location relative to the surrounding vessels, the nature or origin of the tumor and most important, the presence of extrahepatic spread. To the present day, there is no internationally-accepted consensus regarding the best strategy for the imaging of liver tumors and it depends mostly on the request of the clinician, the condition of the patient and the equipment available in the hospital. Most centers use ultrasound (US), computed tomography (CT) and magnetic resonance



**Fig. 6.** Autophagy assay confirms the presence of perinuclear autophagosomes after staining with the secondary antibody (a) and counterstaining with DAPI of the nucleus (b). Controls are seen in figures c and d

imaging (MRI), but some others techniques are available. These include positron emission tomography (PET), a CT during an arterial portography (CTAP) or during arteriography (CTHA) and even laparoscopy with intraoperative ultrasound [16–18].

CT-based scanning is a more sensitive examination for the detection of focal liver lesions. If it's still not clear enough, MRI has an inherent high soft tissue contrast because tissue-specific electromagnetic parameters such as the T1 and T2 relaxation time effect dominate the signal. So, MRI uses the many types of sequences that investigate a different tissue for each differential diagnosis between healthy and pathological liver parenchyma. By using different contrast mechanisms, the MRI can provide both anatomical and functional information, the chemical shift imaging being an example where information is provided with regard to the intracellular fat content of the liver parenchyma or a focal liver lesion [19, 20].

Staging of the malignant liver mass is aimed to stratify patients into groups with similar prognoses, in order to help choose the best treatment, aid in patient counseling, allow comparisons of the outcome of different therapy protocols and last but certainly not least facilitate a good selection or randomization for research protocols. In the case of HCC, the most widely used in Europe and the US is the Barcelona Clinic Liver Cancer (BCLC) system, proposed in 1999 due to its efficacy in both predicting prognosis and as a guide to select the most appropriate therapy [21]. Even if the BCLC staging was proven to be an efficient tool in prognostics, the treatment algorithm is mostly based on the Spanish experience and is overly conservative with respect to the use of surgery. Patients with large tumors are excluded from surgical resection even if it has been demonstrated a 5-year survival of 25 to 39% after resection, with radiofrequency ablation and ethanol injection recommended for those with multifocal disease that respect the Milan criteria [22]. The AJCC/UICC 6<sup>th</sup> edition TNM staging system is based on a study of the International Cooperative Study Group on Hepatocellular Carcinoma, a analysis of 591 cases from the US, Japan and France, who all underwent surgical resection [23, 24]. The major strength is the use of centralized pathological review, focusing on tumor multifocality, size and presence of microvascular or major vascular characteristics of prognostic significance. It also brings together the data of liver fibrosis and cirrhosis based on the Ishak histological grading, but the most important limitation is that it was developed based only on resected tissue and its applicability to patients undergoing other non-surgical locoregional treatments is questionable [25].

But still, even though we take into consideration the most permissive staging possible, most of the patients diagnosed with a HCC are not eligible for surgical resection. These patients are considered to be incurable and in order to achieve a good quality of life through increased toxicity for the cancer cells and decreased toxicity for the healthy tissue, modern

hepatology must develop a different approach, based on recently published data. This very concept is used in the current study. By experimenting on cancer cells previously proven to have stem-like characteristics, our preliminary *in vitro* results aim to target the small but very aggressive subpopulation thought to be responsible for clinical relapse and patient death.

Encouraging results have emerged from recent data published on breast cancer and point towards metformin, an oral-antidiabetic used for decades in the treatment of type 2 diabetes mellitus, as an efficient anticancer drug. Metformin has been investigated by our team for the treatment of WHO grade III and IV malignant gliomas in the laboratory setting and the results were further confirmed by retrospective epidemiological studies that reported a decrease in cancer risk and also a better response to chemotherapy of diabetic patients with breast cancer treated with metformin [26, 2].

Still, despite compelling evidence of a role of metformin as an anticancer drug, the mechanisms by which metformin exerts its oncostatic actions are yet not fully understood. In the current research paper, we studied the effect of metformin plus PIAF combination chemotherapy on HCC-derived stem-like cells in order to further investigate the basic mechanisms by which this association of drugs exerts its action on the cancer cell. This study demonstrates for the first time that the association between metformin and conventional is linked to the generation of oxidative stress, enhancing its anti-neoplastic action. Recent evidence shows that metformin decreases the reactive oxygen species (ROS) in healthy cells because of its antioxidant and free radical scavenging abilities. Such is the case of normal rat pancreatic islets, where metformin has been proven to reduce the oxidative stress induced by chronic exposure to high free fatty acids and restore the antioxidant status in type 2 diabetic patients. Our results confirm this experiment and furthermore, even if metformin has demonstrated powerful anti-oxidant properties in normal cells, in cancer stem-like ones isolated from a liver tumor it stimulates the production of oxidative stress both alone or in combination with chemotherapy. Increased values of oxidative stress are correlated with decreased proliferation rates, thus contradicting the observation that oxidative stress contributes to drug resistance.

Cellular redox homeostasis is thus maintained by a fine balance between antioxidants and pro-oxidants. Glutathione (GSH) is a critical intracellular antioxidant responsible for maintaining redox balance that can be oxidized to form a more complex structure (GSSG), with the ratio GSH/GSSG being an excellent indicator of oxidative stress in the cells [27]. Decreased GSH levels will indicate the shift of redox equilibrium towards a pro-oxidant state. Our results show that the association between metformin and temozolomide has low values of reduced glutathione, which correlates with the increase production of lipid peroxids.

It is well known that most of the liver pathology, may it be non-alcoholic fatty liver disease (NAFLD), non-alcoholic steatohepatitis (NASH) syndrome, cirrhosis and even hepatocellular carcinoma develop partially due to an underlying constellation of closely related risk factors known as metabolic syndrome or syndrome X [28–30]. With a rapidly growing prevalence in the Western world, this syndrome is characterized by obesity, insulin resistance, hyperinsulinemia, hyperglycaemia, dyslipidemia and hypertension. As the first step in disease appearance and development is the accumulation of triglycerides in the hepatocyte as a result of peripheral insulin resistance. In time, this will result in increased oxidative stress within the liver cell due to excessive production of ROS by the mitochondria and the cytochrome P-450 system and afterwards, an increase in lipid peroxidation, pro-inflammatory cytokine and Fas ligand induction promotes the progression from steatosis to NASH, fibrosis and finally cirrhosis [31–35]. When cirrhosis appears, the natural history of the liver parenchyma most often evolves to either hepatocellular carcinoma or cholangiocarcinoma. Our data is supported by this circuit of pathological changes of the hepatic tissue and it is only natural that a drug known for its action against various features and risk factors of metabolic syndrome via oxidative stress to enhance the effect of various cytotoxic drugs and increase toxicity in the malignant cell while decreasing the same toxic effects in the healthy tissue.

## CONCLUSIONS

Hepatocellular carcinomas are heterogeneous tumors with an unpredictable and most often lethal clinical course. As the molecular approach, previously thought to change the management of a patient diagnosed with this dreadful disease, has proven most often less effective than the classic approach, our research team turned to a drug used in the clinic for decades and combines this oral antidiabetic with best supportive care for advanced stage HCC. Our results confirm previously published papers that report the sensitizing effect of metformin to tamoxifen therapy for women with HER2/neu + breast cancer. Still, further data on animal models and retrospective analysis are needed before we make a step forward in the field, to phase I clinical trials, and start prescribing metformin along with PIAF combination chemotherapy for hepatocellular carcinoma treatment.

## ACKNOWLEDGEMENTS AND FUNDING

This research has never been published before and was financially supported by a research grant of the Iuliu Hatieganu University of Medicine and Pharmacy, granted to Bobe Petrushev — MD. All the experiments were carried out both at the Department of Cancer Immunology, Ion Chiricuta Comprehensive Cancer Center in Cluj Napoca and at the G.I. Core Center at Johns Hopkins University, under the supervision of Ciprian Tomuleasa, MD (Postdoctoral Researcher at The Johns Hopkins University in Baltimore, MD,

USA) and Professor Victor Cristea, MD, PhD (Head of Department and Attending physician in Clinical Gastroenterology and Hepatology at the Octavian Fodor Regional Institute of Gastroenterology and Hepatology, Cluj Napoca, Romania).

## CONFLICTS OF INTEREST

None declared.

## REFERENCES

- Papavramidou N, Fee E, Christopoulou-Aletra H. Jaundice in the Hippocratic corpus. *J Gastrointest Surg* 2007; **11**: 1728–31.
- Lykouras E, Poulakou-Rebelakou E, Ploumpidis DN. Searching the seat of the soul in Ancient Greek and Byzantine medical literature. *Acta Cardiol* 2010; **65**: 619–26.
- Reuben A. The way to a man's heart is through his liver. *Hepatology* 2003; **37**: 1500–2.
- Hammerschmidt DE. Prometheus. *J Lab Clin Med* 2000; **135**: 498.
- Altekruse SF, McGlynn KA, Reichman ME. Hepatocellular carcinoma incidence, mortality, and survival trends in the United States from 1975 to 2005. *J Clin Oncol* 2009; **27**: 1485–91.
- El-Serag HB. Hepatocellular carcinoma. *N Engl J Med* 2011; **365**: 1118–27.
- Ryder SD. British Society of Gastroenterology. Guidelines for the diagnosis and treatment of hepatocellular carcinoma (HCC) in adults. *Gut* 2003; **52**: iii1–8.
- Gonzalez-Angulo AM, Meric-Bernstam F. Metformin: a therapeutic opportunity in breast cancer. *Clin Cancer Res* 2010; **16**: 1695–700.
- Soritau O, Tomuleasa C, Aldea M, *et al.* Metformin plus temozolomide-based chemotherapy as adjuvant treatment for WHO grade III and IV malignant gliomas. *J BUON* 2011; **16**: 282–9.
- Jiralerspong S, Palla SL, Giordano SH, *et al.* Metformin and pathologic complete responses to neoadjuvant chemotherapy in diabetic patients with breast cancer. *J Clin Oncol* 2009; **27**: 3297–302.
- von Delius S, Lersch C, Mayr M, *et al.* Capecitabine for treatment of advanced hepatocellular carcinoma. *Hepato-gastroenterology* 2007; **54**: 2310–4.
- Yeo W, Mok TS, Zee B, *et al.* A randomized phase III study of doxorubicin versus cisplatin/interferon alpha-2b/doxorubicin/fluorouracil (PIAF) combination chemotherapy for unresectable hepatocellular carcinoma. *J Natl Cancer Inst* 2005; **97**: 1532–8.
- Tomuleasa C, Soritau O, Rus-Ciucu D, *et al.* Isolation and characterization of hepatic cancer cells with stem-like properties from hepatocellular carcinoma. *J Gastrointest Liver Dis* 2010; **19**: 61–7.
- Tomuleasa C, Soritau O, Fischer-Fodor E, *et al.* Arsenic trioxide plus cisplatin/interferon  $\alpha$ -2b/doxorubicin/capecitabine combination chemotherapy for unresectable hepatocellular carcinoma. *Hematol Oncol Stem Cell Ther* 2011; **4**: 60–6.
- Korde SD, Basak A, Chaudhary M, *et al.* Enhanced nitrosative and oxidative stress with decreased total antioxidant capacity in patients with oral precancer and oral squamous cell carcinoma. *Oncology* 2011; **80**: 382–9.
- El-Serag HB, Marrero JA, Rudolph L, Reddy KR. Diagnosis and treatment of hepatocellular carcinoma. *Gastroenterology* 2008; **134**: 1752–63.

17. Forner A, Reig ME, de Lope CR, Bruix J. Current strategy for staging and treatment: the BCLC update and future prospects. *Semin Liver Dis* 2010; **30**: 61–74.
18. Silva MA, Hegab B, Hyde C, *et al.* Needle track seeding following biopsy of liver lesions in the diagnosis of hepatocellular cancer: a systematic review and meta-analysis. *Gut* 2008; **57**: 1592–6.
19. Suh YJ, Kim MJ, Choi JY, *et al.* Differentiation of hepatic hyperintense lesions seen on gadoxetic acid-enhanced hepatobiliary phase MRI. *Am J Roentgenol* 2011; **197**: W44–52.
20. El-Serag HB. Surveillance for hepatocellular carcinoma: in whom and how? *Therap Adv Gastroenterol* 2011; **4**: 5–10.
21. Llovet JM, Bruix C, Bruix J. Prognosis of hepatocellular carcinoma: the BCLC staging classification. *Semin Liver Dis* 1999; **19**: 329–38.
22. Forner A, Reig ME, de Lope CR, Bruix J. Current strategy for staging and treatment: the BCLC update and future prospects. *Semin Liver Dis* 2010; **30**: 61–74.
23. Varotti G, Ramacciato G, Ercolani G, *et al.* Comparison between the fifth and sixth editions of the AJCC/UICC TNM staging systems for hepatocellular carcinoma: multicentric study on 393 cirrhotic resected patients. *Eur J Surg Oncol* 2005; **31**: 760–7.
24. Zhou L, Rui JA, Wang SB, *et al.* LCSGJ-T classification, 6th or 5<sup>th</sup> edition TNM staging did not independently predict the long-term prognosis of HBV-related hepatocellular carcinoma after radical hepatectomy. *J Surg Res* 2010; **159**: 538–44.
25. Zhou L, Rui JA, Ye DX, *et al.* Edmondson-Steiner grading increases the predictive efficiency of TNM staging for long-term survival of patients with hepatocellular carcinoma after curative resection. *World J Surg* 2008; **32**: 1748–56.
26. Dowling RJ, Goodwin PJ, Stambolic V. Understanding the benefit of metformin use in cancer treatment. *BMC Med* 2011; **9**: 33.
27. Hadad S, Iwamoto T, Jordan L, *et al.* Evidence for biological effects of metformin in operable breast cancer: a pre-operative, window-of-opportunity, randomized trial. *Breast Cancer Res Treat* 2011; **128**: 783–94.
28. Burhans WC, Heintz NH. The cell cycle is a redox cycle: linking phase-specific targets to cell fate. *Free Radic Biol Med* 2009; **47**: 1282–93.
29. Donohoe CL, Pidgeon GP, Lysaght J, Reynolds JV. Obesity and gastrointestinal cancer. *Br J Surg* 2010; **97**: 628–42.
30. Lackner C. Hepatocellular ballooning in nonalcoholic steatohepatitis: the pathologist's perspective. *Expert Rev Gastroenterol Hepatol* 2011; **5**: 223–31.
31. Lebovics E, Rubin J. Non-alcoholic fatty liver disease (NAFLD): why you should care, when you should worry, what you should do. *Diabetes Metab Res Rev* 2011; **27**: 419–24.
32. Liu Q, Bengmark S, Qu S. The role of hepatic fat accumulation in pathogenesis of non-alcoholic fatty liver disease (NAFLD). *Lipids Health Dis* 2010; **9**: 42.
33. Mirza MS. Obesity, visceral fat, and NAFLD: querying the role of adipokines in the progression of nonalcoholic fatty liver disease. *ISRN Gastroenterol* 2011; 2011: 592–404.
34. Kashyap SR, Diab DL, Baker AR, *et al.* Triglyceride levels and not adipokine concentrations are closely related to severity of nonalcoholic fatty liver disease in an obesity surgery cohort. *Obesity (Silver Spring)* 2009; **17**: 1696–701.
35. Welzel TM, Graubard BI, Zeuzem S, *et al.* Metabolic syndrome increases the risk of primary liver cancer in the United States: a study in the SEER-Medicare database. *Hepatology* 2011; **54**: 463–71.